



Case Presentation

Traumatic Brain Injury

- 48 year old female
 - Multiple vehicle accident resulting in loss of consciousness; less than 1 minute.
 - Enrolled in a Masters program.
- Two years post accident, patient evaluated for short term memory dysfunction, problems with attention and concentration, and inability to organize thoughts that prevented a return to work.
 - Drop out of Masters program.
- Scan 1: Base line before treatment.
- Scan 2: Scan after 1 HBOT showing areas of recoverable brain tissue.
- Scan 3: Scan after 40 treatments

Result: Patient able to return to her Masters program and complete it. Now working as a research assistant and today employed by Louisiana State University as a NIH grant coordinator.

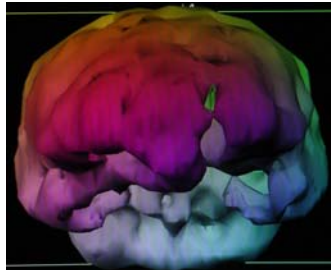
LHE April 27, 2004
Copyright Retained
Paul G. Harch, M.D. 2004



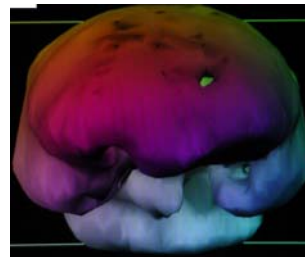
Case Presentation

Traumatic Brain Injury

48 y. female

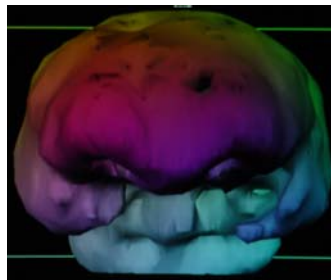


Baseline



1 HBOT

Diagnostic showing
recoverable brain tissue



40 HBOT

LHE April 27, 2004
Copyright Retained
Paul G. Harch, M.D. 2004



Case Presentation

Dementia

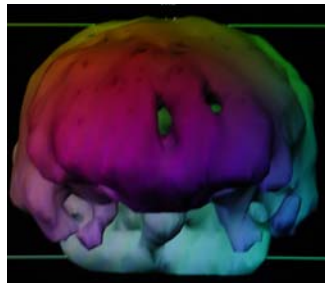
- 72 year old demented man facing institutionalization.
 - * Behavior completely inappropriate and required his removal from his children's home.
 - * Long history of alcohol & tobacco abuse with several traumatic brain injuries and carbon monoxide exposure.
- Four month history of sudden onset of nightly confusion, memory loss, inappropriate behavior, paranoia, etc.
 - * Folstein Mini-Mental status-15/30 (moderately severe demented).
- Scan 1: Base Line – Major damage to frontal and temporal lobes.
- Scan 2: Scan after 1 HBOT showing recoverable tissue.
- Scan 3: Scan after 40 HBOT treatments over 6 weeks.
- Global cognitive improvement, increase in energy level, improved mood, absence of confusional episodes, improved sleep, weight gain.
 - * Repeat of Folstein Scale = 22 (Mild Dementia).
- Now living semi-independently with minimal help.

LHE April 27, 2004
Copyright Retained
Paul G. Harch, M.D. 2004

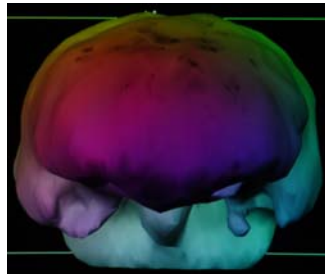


Case Presentation

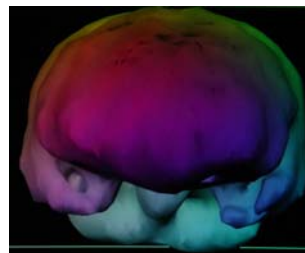
Dementia 72 y. male



Baseline



40 HBOT



1 HBOT

Diagnostic showing
recoverable brain tissue

LHE April 27, 2004
Copyright Retained
Paul G. Harch, M.D. 2004



Case Presentation

Autism & Persistent Developmental Delay (PDD)

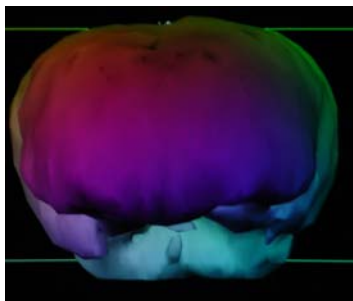
- 7 year old male who is repeating kindergarten.
 - * Born one week overdue and a difficult labor, becoming "stuck" in the birth canal and requiring forceps extraction.
 - * Global developmental delay. Patient on Ritalin and Prozac.
- Main problems included poor enunciation, limited vocabulary, short, nearly unintelligible sentences, no coordination, 2 year cognitive delay, attention deficit, emotional outbursts, autistic behavior, and drooling.
- Scan 1: Baseline scan shows decreased flow, to the frontal lobes and both temporal lobes, especially the left.
- Scan 2: 1 HBOT treatment shows recoverable tissue & improvement to both temporal lobes.
- Patient received 40 HBOTs and weaned from Ritalin and Prozac.
 - * Drooling gone, speech and cognition improved.
 - * Dad stated that the attention deficit was "1000% improved and emotional outbursts and autistic tendencies 100,000%" improved.
- Patient received another 25 HBOT treatments over the next year and continued to globally improve. He now speaks in full sentences and very active in sports for the first time in his life.
 - * He continues to be medication free.

LHE April 27, 2004
Copyright Retained
Paul G. Harch, M.D. 2004

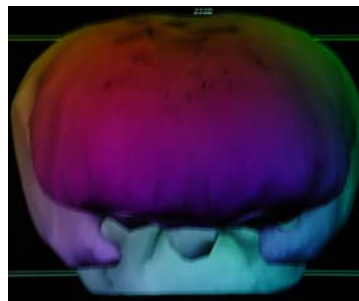


Case Presentation

Autism & Persistent Developmental Delay (PDD) 7 y. male



Baseline



1 HBOT
Diagnostic showing
recoverable brain tissue

LHE April 27, 2004
Copyright Retained
Paul G. Harch, M.D. 2004